

## Ultrasound Images

### Managing Hemorrhage as a Complication of Uterine Aspiration

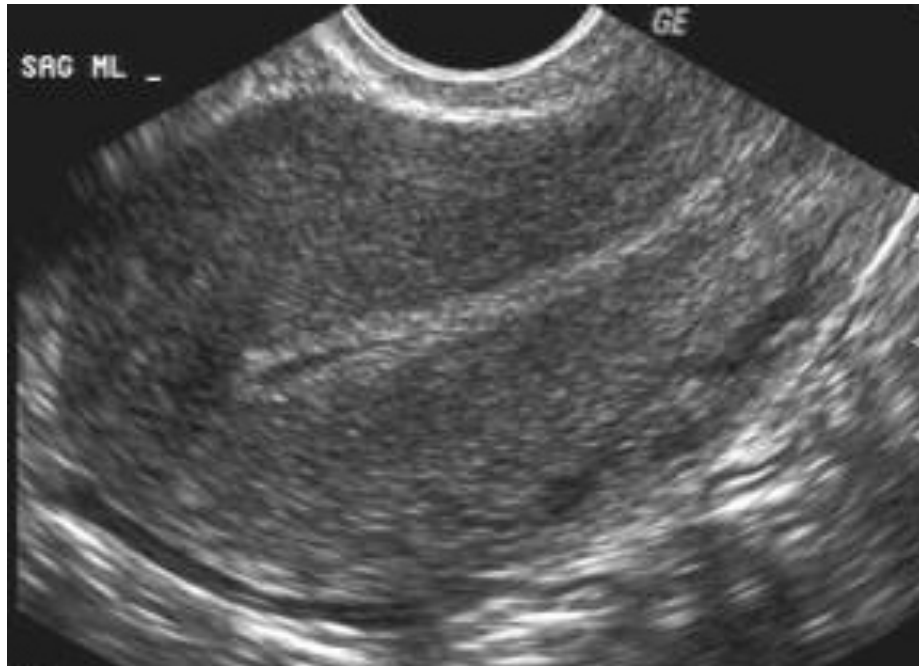


Figure 1. Empty Uterus (longitudinal view)

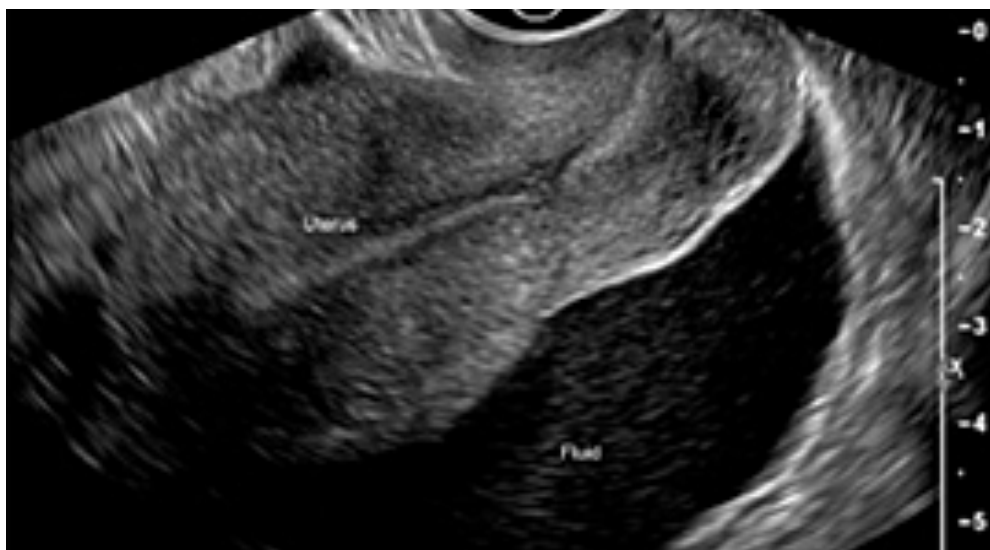

Figure 2. Uterus with free fluid in cul-de-sac (longitudinal view)